

DENTINO
JURNAL KEDOKTERAN GIGI
Vol VI. No 2. September 2021

THE EFFECT OF BINJAI (*Mangifera caesia*) LEAVES EXTRACT GEL TO FIBROBLAST CELL NUMBER ON INCISION WOUND

Noor Hildayanti¹), Irham Taufiqurrahman²), Renie Kumala Dewi³)

¹)Dentistry Faculty, Lambung Mangkurat University, Banjarmasin, Indonesia

²)Oral and Maxillofacial Surgery Department, Dentistry Faculty, Lambung Mangkurat University, Banjarmasin, Indonesia

³)Pediatric Dentistry Department, Dentistry Faculty, Lambung Mangkurat University, Banjarmasin, Indonesia

ABSTRACT

Background: The ethanol extract of binjai leaves contains bioactive compounds that are saponin, tannin, triterpenoid, steroid, alkaloid and flavonoid which potentially as an anti-inflammation, anti-bacterial, and antioxidant. It can fasten and control the process of scar healing. The binjai leaves extract was made into gel preparation. The binjai leaves extract gel can affect fibroblast cell number during the proliferation phase. **Purpose:** To analyze the effect of binjai (*Mangifera caesia*) leaves extract gel to the fibroblast cell number on male wistar rats (*Rattus norvegicus*) incision wound. **Methods:** This research design was a true laboratory experimental research with post-test only with control group design which used 24 male wistar rats and divided into 4 groups: the negative control group that was given the placebo gel and the treatment group that was given the binjai leaves extract gel with 5%, 10%, and 15% concentrations. **Results:** The result of Two-way ANOVA statistic test shows that there is a meaningful difference in the treatment group on the 7th day ($p=0,000$) and on the 14th day ($p=0,000$). The Post-Hoc Bonferroni test for fibroblast cell number on the 7th and 14th day shows that there is a meaningful difference ($p<0,05$) between the negative control group and the treatment group. **Conclusion:** Binjai leaves extract gel have an effect to the fibroblast cell number on male wistar rats incision wound with the most effective concentration of 15%.

Keywords: Binjai leaves extract gel, Fibroblast cell number, Flavonoid, Incision wound healing

Correspondence: Noor Hildayanti, Dentistry Faculty Lambung Mangkurat University, Jl. Veteran No. 128B, Melayu, Banjarmasin Tengah, Banjarmasin, South Kalimantan 70122, email: eldanhy3@gmail.com

INTRODUCTION

The scar is an anatomical damage with a separate mild condition caused by trauma. After the forming of scar, it is continued with the scar healing process. This process consists of few phases, which are inflammation phase, proliferation phase, and maturation.¹ In the proliferation phase, there will be the increasing of cell number that is fibroblast cell. The fibroblast cell peaked on the 7th day and decreased on the 14th day.^{2,3,4}

The fibroblast is a primary cell that found in the proliferation phase, which indicated that there is a gradual healing process. The fibroblast involves four components: fibroblast proliferation, ECM deposition (extracellular matrix), maturation and fibrous tissue organization (remodelling).⁵ The fibroblast also has a primary function in the

forming of solvent tissue and collagen in the scar healing.⁶

The scar healing can be conducted by many ways, one of which is by herbal medicine that came from a plant as an adjuvant therapy. The adjuvant therapy is a treatment that designed to help reach a goal.⁷ The most commonly found plant in South Kalimantan is binjai (*Mangifera caesia*) which included in *Mangifera* genus and *Anacardiaceae* family.⁶

Based on the phytochemical test of the previous research, binjai leaves have contents such as saponin, tannin, triterpenoid, steroid, alkaloid, and flavonoid.⁸ There is high amount of flavonoid in binjai leaves. The flavonoid is an anti-inflammation and anti-microbe that useful in the scar healing process.^{9,10} The flavonoid function as anti-inflammation and affect in fibroblast cell proliferation.¹¹

The flavonoid compound also plays a role as an antioxidant in the scar healing process and fasten the epithelialization. Epithelialization is a scar covering process with new epithelium. The scar healing can be fastened with the help of contained flavonoid in the binjai plant, known the highest flavonoid value in binjai leaves is 32,63 mg/QE with the room drying process.¹²

Based on the description above, this research was conducted to find out the effect of binjai leaves extract gel with 5%, 10%, and 15% concentrations to the fibroblast cell number on the 7th day and 14th day on male wistar rat's back incision wound.

MATERIALS & METHODS

This research was conducted after the ethical clearance was issued by Health Research Ethical Committee Dentistry Faculty ULM with No.060/KEPKGFKGULM/EC/I/2020. This research was a true experimental research with post-test only with control group design. The used sample is 24 male wistar rats, divided into 4 groups which are the treatment groups consisted of the binjai leaves extract gel with 5%, 10%, and 15% concentrations and the without extract gel on the 7th day and 14th day group.

The making of the extract used maceration method. The binjai leaves extract was made by the binjai leaves that cleaned, naturally dried, and mashed up until simplicia powder was obtained. The binjai leaves simplicia were soaked for 3x24 hours in 70% ethanol solvent. The maceration result was vaporized using a rotary evaporator with 37°C heating temperature and vaporized again in the water bath until the thick extract was obtained.

The 100% pure binjai leaves thick extract was made into 5%, 10%, and 15% concentrations gel. The binjai leaves extract gel was made by dissolving the HPMC with aquadest until it dissolved in 15 minutes and left it for 24 hours. The HPMC was mixed with Propylenglycol and Tween 20 and stirred quickly. The binjai leaves extract was added and stirred quickly, then add the peppermint oil, lastly add 100g of aquadest.

The experimental animals were adapted in a laboratory environment for 7 days, then taken and conducted the measuring of back part for the making of a scar. The fur on the back area were shaved with length 5 cm and height 3 cm then disinfected using alcohol before treatment. The incision wound was made as long as 20 mm with subcutis depth in the back left area of wistar rat, aligned with os. vertebrae, with 50 mm distance from the ear using No. 15 blade scalpel. The blood was cleaned using cotton and was given aquadest.

The binjai leaves extract gel applicated on the wound topically using a cotton bud in each

experimental animal. The application of the gel was repeated 1x, then 1 sterile cotton bud used in 1 concentration and 1 wound with the weight of the gel was 100 mg. The scar treatment was conducted every day for 14 days.

The extract gel was applied 1 time a day, then the scar was covered with a damp gauze. On the 7th day and 14th day, the wistar rat in each group euthanized using mixed anaesthetic of Ketamine 40-100 mg/kg and Xylazine dose 5-10 mg/kg intraperitonally until the wistar rat dead. The taken of tissue was using biopsy method on the insicioun wound area with the length 30 mm, width 3 mm, and subcutis depth.

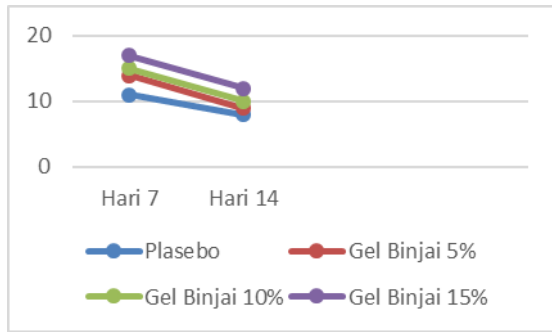
Each of the biopsy result specimen of every treatment was taken into histopathology preparation and conducted the haematoxyllin eosin coloring, then conducted the preparation reading. The obtained data from this research are quantitative data of fibroblast cell number. The statistic analysis was using Two-way ANOVA hypothesis test with 95% confidence level ($\alpha = 0,05$), continued with the Post Hoc Bonferroni test to find out the meaning value.

RESULTS

The statistic result shows that the data of all groups are normally distributed ($p > 0,05$) and homogenous ($p > 0,05$). The average result of the fibroblast cell number on the wistar rat incision wound can be seen in table 1. The average graphic of the fibroblast cell number on the wistar rat incision wound for 14 days can be seen in picture 1.

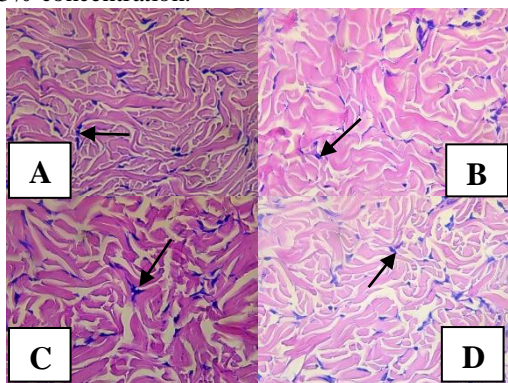
Table 1. The average (Mean \pm SD) of the fibroblast cell number on the wistar rat incision wound

Kelompok	Mean \pm SD Jumlah Sel	
	Hari ke-7	Hari ke-14
Gel Plasebo	10,66 \pm 1,52 (9-11 sel)	7,66 \pm 0,57 (6-8 sel)
Binjai 5%	13 \pm 2 (12-14)	8 \pm 3,60 (7-9)
Binjai 10%	13,33 \pm 2,51 (12-15)	8,33 \pm 0,57 (7-10)
Binjai 15%	16,33 \pm 1,52 (15-17)	11,33 \pm 2,08 (10-12)



Picture 1. The average of the fibroblast cell number on the wistar rat incision wound on the 7th day and 14th day.

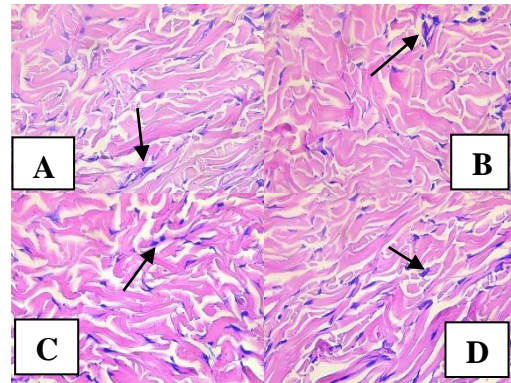
Picture 1 shows the difference of the fibroblast cell number on the wistar rat incision wound on the 7th day 14th day. The 7th day average shows the increasing of fibroblast cell number and on the 14th day shows the decreasing of the fibroblast cell number. Based on the diagram, the increasing of fibroblast cell number on the 7th day sequentially in the 15% concentration of binjai leaves extract gel group, the 10% concentration, the 5% concentration and the placebo gel group. The lowest fibroblast cell number on the 14th day sequentially in the placebo gel group, the 5% concentration of binjai leaves extract gel group, the 10% concentration, and the 15% concentration.



Picture 2. The histopathology illustration of wistar rat's scar healing fibroblast cell in the control group (A), 5% binjai leaves extract gel (B), 10% binjai leaves extract gel (C), 15% binjai leaves extract gel (D) on the 7th day with 400x zoom using light microscope.

Picture 2 shows the histopathological images of fibroblast cells on the 7th day with 400x magnification of the skin tissue of Wistar rats incision wound given placebo gel has fibroblast cells number as many as 9-11 cells, binjai leaf extract gel given with a concentration of 5% has the fibroblast cells number of 12-14 cells, 10%

concentration has 12-15 cells, and 15% concentration has 15-17 cells.



Picture 3. The histopathology illustration of wistar rat's scar healing fibroblast cell in the control group (A), 5% binjai leaves extract gel (B), 10% binjai leaves extract gel (C), 15% binjai leaves extract gel (D) on the 14th day with 400x zoom using light microscope.

Picture 3 shows the histopathological images of fibroblast cells on the 14th day with 400x magnification of the skin tissue of Wistar rats with incision wound given placebo gel has fibroblast cells number as many as 6-8 cells, binjai leaf extract gel given with a concentration of 5% has the fibroblast cells number of 7-9 cells, 10% concentration has 7-10 cells, and 15% concentration has 10-12 cells.

DISCUSSION

The research result shows that the binjai leaves extract gel can increase the fibroblast cell number on the 7th day and decrease the fibroblast cell number on the 14th day compared with the placebo gel group. The incision wound on the rat will go through the scar healing process that is inflammation phase, proliferation phase, and maturation phase. The fibroblast produced extracellular matrix, primary collagen, and fibronectine for migration and cell proliferation.¹⁴

The fibroblast cell statistic test on the experimental animal that has been applied with binjai leaves extract gel in the incision wound obtained more fibroblast cell number than placebo gel. The increased fibroblast cell number on the 7th day between the placebo gel group as control and the 5%, 10%, and 15% concentrations of binjai leaves extract gel shows a meaningful difference ($p < 0,05$) with the highest average is the 15% concentration of binjai leaves extract gel group with 16,333 average. The statistic test result on the 7th day shows the increasing of the fibroblast cell number and the comparison between each group shows that the highest average of the fibroblast cell number is in the 15% concentration of binjai leaves extract gel group, then followed by the 10%

concentration, the 5% concentration and the placebo gel group. The increasing of the fibroblast cell number on the 7th day corresponds with the research by Khowariro et al (2018) which conducted a research regarding the effect of the red fruit oil application to the fibroblast cell number on the back of wistar rat with IIA degree of burn and stated that the fibroblast reach its peak on the 7th day.

The binjai leaf contains saponin, flavonoid, and tannin which functions as an antioxidant and anti-microbe that can help the process of scar healing. The flavonoid content in the binjai leaf is 168,129 µg/mg (Rosita *et al*, (2019). The flavonoid can increase epithelial cell proliferation, form the granulation tissue, and increase migration also miofibroblast activity.¹³

The meaningful difference between the binjai leaves extract gel groups and the control group happened because of the flavonoid content in the binjai leaf which has anti-inflammatory effect, so it can fasten the scar healing. The flavonoid compound activity can increase fibroblast number.¹⁶

On the 7th day, the 15% concentrations of binjai leaves extract gel has the higher fibroblast cell average number compared with the 5%, 10% concentrations of binjai leaves extract gel and the control group. This corresponds to the theory that was stated by Kurnia et al (2015) which called the potency of green tea extract (*Camellia sinensis*) to the increasing of the fibroblast cell number post tooth extraction on wistar rat. The green tea extract is a natural material and has been proven of its capability to increase the fibroblast cell number of male wistar rat's post tooth extraction. The substance in green tea that has advantages for the process of scar healing is flavonoid.¹⁷

The flavonoid can fasten the tissue regeneration in the scar healing process and is a natural antioxidant. This increasing happened because of the reduced inflammation process, then entered the early stage of fibroplasia process with the fibroblast proliferation in the area of the scar. The fibroblast in the tissue moved from the edge of scar along the fibrin fibre in the scar. The fibroblast reaches its peak on the 7th day. According to Sumbayak (2015), the fibroblast proliferation in the scar healing process was naturally stimulated by interleukin-Ib (IL-Ib), platelet derived growth factor (PDGF), and fibroblast growth factor (FGF).¹⁸ According to Ardiana et al (2015), saponin can increase the monocytes proliferation so it can increase the macrophage number. The macrophages secrete the growth factors such as FGF, PDGF, TGF-β, and EGF that will pull the fibroblast to the scar area,

synthesize the collagen and increase the proliferation of capillary blood vessels.⁶

On the 14th day, the 15% concentrations of binjai leaves extract gel has the higher average number of fibroblast cell than the 5%, 10% concentrations of binjai leaves extract gel and the control group. The fibroblast cell was decreased on the 14th day. This supported by the research by Rosa et al (2018) which titled the effect of the yellow potato gel (*Solanum tuberosum L.*) to the scar healing process on the mice (*Mus musculus*). The yellow potato gel has been proven to has flavonoid in the form of anthocyanin. The flavonoid is one of the antioxidant substances that has anti-inflammatory effect.¹⁹ In the research by Khowariro (2018), on the 14th day, the forming of collagen happened from the 7th day. Then, the scar healing process entered the remodelling phase on the 14th day. On the 14th day, it was described as the final proliferation phase where the fibroblast produced a big collagen.⁴

This research result shows that the 15% concentrations of binjai leaves extract gel gave a better effect than the 5% and 10% concentrations of binjai leaves extract gel. This can be seen from the fibroblast cell number that experienced the highest increasing compared with the fibroblast number in the other group on the 7th day. There is the decreasing of the fibroblast number on the 14th day. The result of this study indicates that the binjai leaf extract gel can help the wound healing process. Still, based on the statistical test, there is no significant effect of the relationship with the gel concentration. This is probably because the number of days observed was too few, namely on the 7th day to determine the increase in fibroblast cells, and the 14th day to determine the decrease in fibroblast cells. The concentration variation of the gel also suspected to affect this research result, the higher gel concentration suspected to give more significant effect to the fibroblast cell number. This research has an obstacle that is the bad gel concentration. Based on this research, it can be concluded that there is an effect of binjai leaves extract gel to the increased number of fibroblast cell on the 7th day and the reduced number of fibroblast cell on the 14th day in the healing of the male wistar rat's back incision wound with the most effective concentration of 15%.

REFERENCES

1. Sorongan RS, Pangemanan DHC, Siagian KS. Efektivitas Perasan Daun Pepaya Terhadap Aktivitas Fibroblas Pasca Pencabutan Gigi Pada Tikus Wistar Jantan. *Pharmaco* jurnal Ilmiah Farmasi – Unsrat. 2015; 4 (4): 52-57.

2. Sabirin IPR, Maskoen AM, Hernowo BS. Peran Ekstrak Etanol Topikal Daun Mengkudu (*Morinda citrifolia L.*) pada Penyembuhan Luka Ditinjau dari Imunoekspresi CD34 dan Kolagen pada Tikus Galur Wistar. MKB. 2015; 45 (4): 226-233. Sapara TU, Waworuntu O, Juliatri. Efektivitas Antibakteri Ekstrak Daun Pacar Air (*Impatiens balsamina L.*) Terhadap Pertumbuhan *Phorphyromonas gingivalis*. Jurnal Ilmiah Farmasi. Desember 2016; 4(5): 2302-2493.
3. Dewi PS. Efektifitas Ekstrak Lidah Buaya Terhadap Jumlah Sel Fibroblas Pada Proses Penyembuhan Luka Insisi Marmut. Intisari Sains Medis 2018; 9 (3): 51-54.
4. Khowariro MI. Pengaruh Pemberian Minyak Buah Merah Terhadap Jumlah Sel Fibroblas Pada Punggung Tikus Jantan Galur Wistar Dengan Luka Bakar Derajat IIA. Jurnal Pendidikan dan Humaniora. 2018; 2 (3): 259-272.
5. Masir O, Menkher Manjas M, Putra AE, Agus S. Pengaruh Cairan *Cultur Filtrate* Fibroblas (CFF) Terhadap Penyembuhan Luka; Penelitian eksperimental pada *Rattus Norvegicus* Galur Wistar. Jurnal Kesehatan Andalas. 2012; 1 (3): 112-117.
6. Ardiana T, Kusuma ARP, Firdausy MD. Efektivitas Pemberian Gel Binahong (*Anredera Cordifolia*) 5% Terhadap Jumlah Sel Fibroblas Pada Soket Pasca Pencabutan Gigi Marmut (*Cavia Cobaya*). *Odonto Dental Journal*. 2015; 2 (1): 64-70.
7. Shiel WC. *Definition of Adjuvant Therapy*. Available from <https://www.rxlist.com/script/main/art.asp?articlekey=2151>. Reviewed November, 2018.
8. Darmayanta HI, Edyson, Budiarti LY. Aktivitas Hambat Ekstrak Etanol Daun Binjai (*Mangifera Caesia Jack*) Terhadap *Salmonella typhi* Dan *Shigella dysenteriae* In Vitro. *Homeostasis*. 2019; 2 (2): 233-240.
9. Mohammed M.S, Osman W.J.A, Garelnabi E.A.E, Osman Z, Osman B, Khalid H.S, Mohammed M.A. *Secondary Metabolites As Anti-Inflammatory Agents*. *The Journal of Phytopharmacology*. 2014; 3 (4): 275-285.
10. Yunanda V, Rinanda T. Aktivitas Penyembuhan Sediaan Topikal Ekstrak Bawang Merah (*Allium Cepa*) Terdapat Luka Sayat Kulit Mencit (*Mus Musculus*). Jurnal Veteriner. 2016; 7(14): 606-614.
11. Anwar K, Fadlillaturrahmah, Sari DP. Analisis Kandungan Flavonoid Total Ekstrak Etanol Daun Binjai (*Mangifera Caesia Jack*) Dan Pengaruhnya Terhadap Kadar Glukosa Darah Tikus Yang Diinduksi Fruktosa-Lemak Tinggi. Jurnal Ilmiah Ibnu Sina. 2017; 2 (1): 20-30.
12. Syafarina M, Taufiqurrahman I, Edyson. Perbedaan Total Flavonoid Antara Tahapan Pengeringan Alami Dan Buatan Pada Ekstrak Daun Binjai (*Mangifera caesia*). Dentino Jurnal Kedokteran Gigi. April 2017; 1(1): 84-88.
13. Palumpun EF, Wiraguma AAGP, Pangkahila W. Pemberian ekstrak daun sirih (*Piper betle*) secara topikal meningkatkan ketebalan epidermis, jumlah fibroblas, dan jumlah kolagen dalam proses penyembuhan luka pada tikus jantan galur Wistar (*Rattus norvegicus*). Jurnal e-Biomedik. 2017; 5 (1).
14. Sugiaman VK. Peningkatan Penyembuhan Luka di Mukosa Oral Melalui Pemberian Aloe Vera (Linn.) Secara Topikal. JKM. 2011; 11(1): 70-79.
15. Rosita JM, Taufiqurrahman I, Edyson. Perbedaan Total Flavonoid Antara Metode Maserasi Dengan Sokletasi Pada Ekstrak Daun Binjai (*Mangifera Caesia*) (Studi Pendahuluan Terhadap Proses Pembuatan Sediaan Obat Penyembuhan Luka). Jurnal Kedokteran Gigi. April 2017; 1(1): 100-105.
16. Napanggala A, Susianti, Apriliana E. Pengaruh Pemberian Getah Tanaman Jarak Pagar (*Jatropha Curcas L.*) Secara topikal Terhadap Tingkat Kesembuhan Luka Iris Pada Tikus Putih Jantan Galur Sprague Dawley. Jurnal Medika. 2014; 3(5): 26-35.
17. Kurnia PA, Ardhiyanto HB, Suhartini. Potensi Ekstrak Teh Hijau (*Camellia sinensis*) terhadap Peningkatan Jumlah Sel Fibroblas Soket Pasca Pencabutan Gigi pada Tikus Wistar. e-Jurnal Pustaka Kesehatan. Januari 2015; 3 (1): 122-127.
18. Sumbayak EM. Fibroblas: Struktur dan Peranannya dalam Penyembuhan Luka. Jurnal Kedokteran Meditek. 2015; 21 (57).
19. Rosa SA, Adi S, Achadiyani A, Khairani AF, Lantika UA. Efek Gel Kentang Kuning (*Solanum Tuberosum L*) Terhadap Proses Penyembuhan Luka Pada Mencit (*Mus Musculus*). E-Journal Unisba. 2018; 6(1): 21-27