

## CONCOMITTAN HYPERURICEMIA AND ABCESS MID THORACIC REGION: THE USE OF DUAL ENERGY CT SCAN

**Feda Makkiyah**

Faculty of Medicine, University of Pembangunan Nasional Veteran, Jakarta

Correnpondence email: [fedaanisah@upnvj.ac.id](mailto:fedaanisah@upnvj.ac.id)

**Abstract:** *Dual energy scan was performed to differentiate any collection associated with calsium. Case report. This 23 year old man showed severe hyperuricemia and mid thoracic pain and MRI showed collection over posterior epidural thecal sac over T3 until T9. Dual energy CT scan was performed to assess uric acid crystal over thoracic region. The CT result was negative. He was treated over intravenous antibiotic and pain medication. His pain improved progressively and laboratory results showed towards normal value and he was discharged on day twelveth. Conclusion. This case report showed the comprehensive diagnostic tool to yield out the aetiology of thoracal epidural collection, despite negative result.*

**Keywords:** *Hyperuricemia, abcess, mid thoracic, dual energy, CT scan*

## INTRODUCTION

DECT (dual energi CT scan) is a non-invasive method for the identification of MonoSodium Urate (MSU) crystal deposits. The use of dual energy CT have increased remarkably nowadays to diagnose hyperuricemia. This article aims to demonstrate the use of DECT in helping diagnosis of hyperuricemia.

## CASE REPORT

A 23 year old male came to emergency department with severe progressive upper back region pain. He had a history of GOUT arthritis. Physical examination showed tachycardia, and mild fever. He had tenderness over T2-T9, and no neurological deficits. His laboratory value showed severe hyperuricemia, ESR and leucocyte blood value were remarkably increased.

MRI thoracic spine findings showed the epidural lesion from T3/4 to T9 that contacted posterior aspect of the thoracic cord, and centered at level Th 5/6 (Figure 1). No anterior displacement of the thecal sac. No evidence of cord compression or abnormal cord signal. Because of hyperuricemia, dual energy CT with a Siemens 4 CT was performed to assess whether uric acid crystals were the source of backpain.

CT scan showed the thoracic spinal alignment was normal and no fracture, focal erosions or bony lesions detected. There was no canal or foraminal stenosis with normal outline appearance of the central spinal canal and neural foramina. The thecal sac outline appearance was normal and no obvious disc bulge or protrusion, or collections identified. There was no other soft tissue abnormality, or uric acid deposition identified, and no other incidental findings were noted. Upon neurosurgical consultation, conservative treatment with antibiotics were chosen. However, there was a concern of emergency operation whenever there was neurological deficits. He showed

improvement with antibiotics and pain medication. He was discharged on day twelveth.

## DISCUSSION

Low back pain is a very ordinary health problem and affects work-life in productive ages or disturbs functional life of people who suffer of the entity.

Hyperuricemia is one of the least likely cause of low back pain. However, a clinician should put high priority of hyperuricemia as a cause of back pain, whenever there is a patient of low back pain and elevated serum uric acid.<sup>1</sup>

Hyperuricemia is a condition of disorder of metabolism of protein which normal range in men 3.4-7.2 mg/dL and 2.4-6.1 mg/dL in women elevated. 10% people with hyperuricemia develop gout, which crystals of monosodium urate collected in and around large joints. However, typically gout affect the joints in the peripheral area, rather than in axial joints. A cross sectional study in Pakistan showed that the existence of hyperuricemia in 1 out of 4 patients with low back pain. That study predicted the strong correlation of lumbar disc prolapse and narrowing of joint space in vertebrae with hyperuricemia, however with still unclear mechanism.<sup>2</sup>

In this case report, the patient complained severe back pain with elevated serum uric acid level. This was the plausible reason of high suspicion of monosodium urate as a source of pain and was the content of collection in thoracic epidural space in our current case. To clarify the other differential diagnosis, DECT was performed.

Two- x ray tubes with separated peak kilovoltages (80 and 140 kVP) are required to build the two CT image. The scanned tissue are differentiated by comparing the difference of material-specific contents and projected using special software. Multicolor cross-sectional images are performed from DECT data processing and rendered into 3D surface models. These

models can be used in quantification of tophi (collection of monosodium urate).<sup>3</sup>

This current case report demonstrated DECT was used to reveal any monosodium urate (MSU) deposits in thoracic epidural space in hyperuricemic patients. However, the result showed no collection of MSU.

The systematic literature from seven studies presented that DECT demonstrated relatively high sensitivity (88%) and specificity (90%) in the diagnosis of gout.<sup>4</sup> However, DECT has shown to be limited in sensitivity in short-term gout patients, or first onset patients.<sup>5</sup> Collection

in the thoracic epidural space in this patient was not proven to be MSU. This understandable, because 10% hyperuricemia patients developed gout.<sup>2</sup> Our patient showed improvement with antibiotics and allopurinol.

### CONCLUSION

This case report showed the comprehensive diagnostic tool to yield out the aetiology of thoracic epidural collection, despite negative result.

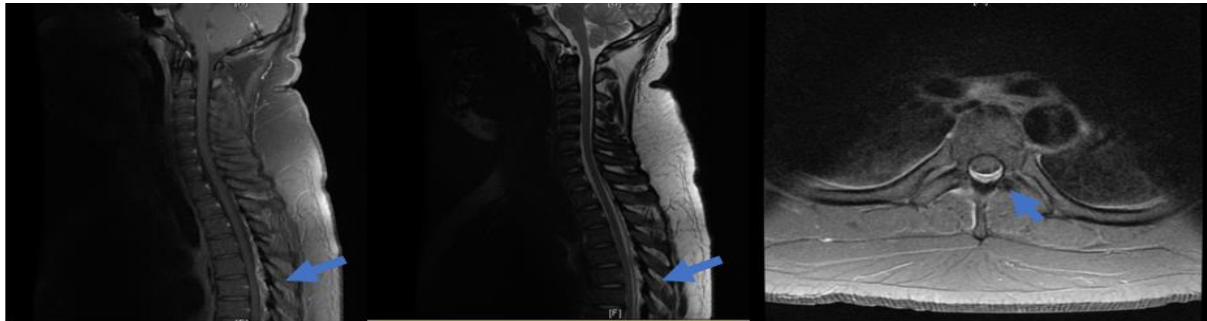

Figure 1. MRI sagittal,axial with contrast. It showed posterior epidural collection

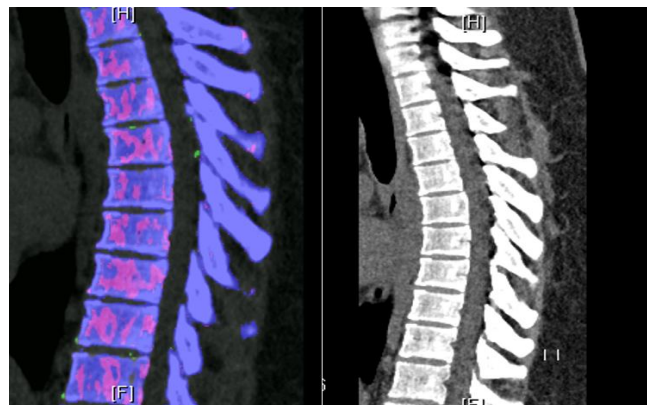


Figure 2. Dual energy CT thoracic. It showed no deposit of uric crystal

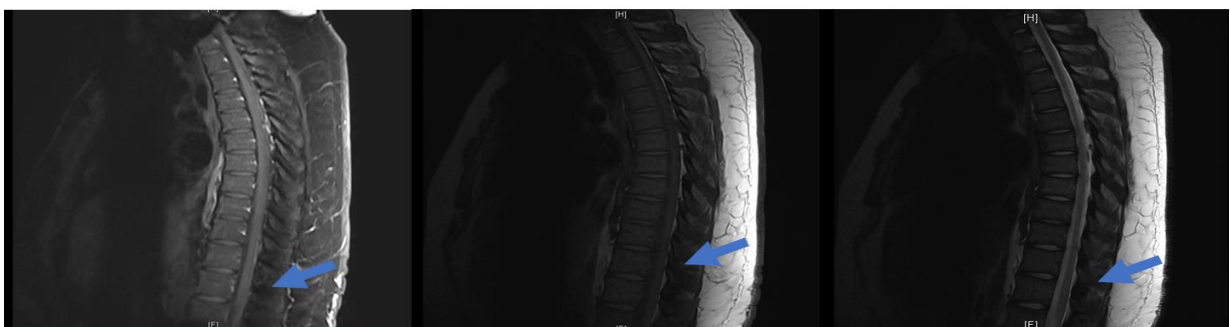

Figure 3. MRI Thoracic with contrast on thirteen day. It showed reduction in size of spinal epidural collection

## **REFERENCES**

1. Elgafy H, Liu X, Herron JJWjoo: Spinal gout: a review with case illustration. 2016;7(11):766.
2. Burhan H, Choudry U, Umerani M, Sharif S, Nisar A: Hyperuricemia in Patients with Chronic Low Back Pain: Experience from a Single Institutional Neurosurgical OPD. *J Surgery Emerg Med.* 2017;1(7).
3. Smith SE. Conventional radiography and computed tomography. *Rheumatology: Elsevier*; 2015. p. 307-21.
4. Yu Z, Mao T, Xu Y, Li T, Wang Y, Gao F, et al.: Diagnostic accuracy of dual-energy CT in gout: a systematic review and meta-analysis. *J Skeletal radiology.* 2018;47(12):1587-93.
5. Jia E, Zhu J, Huang W, Chen X, Li J: Dual-energy computed tomography has limited diagnostic sensitivity for short-term gout. *J Clinical Rheumatology.* 2018;37(3):773-7.