

CORRELATION BETWEEN ENDOBUTTON POSITION AND FUNCTIONAL OUTCOME AFTER ACL RECONSTRUCTION: PLAIN XRAY EVALUATION

Mahyudin, Ricky Wibowo, Ghuna ArioHarjo Utoyo

Department of Orthopaedics and Traumatology
Faculty of Medicine Universitas Padjadjaran
dr. Hasan Sadikin General Hospital, Bandung

Correspondence email: mahyudin307@gmail.com

Abstract: *The correct positioning of the femoral tunnel and endobutton position determine the success of ACL reconstruction (ACLR). Improper femoral tunnel placement most common errors in failed ACLR. However, plain post-operative imaging in the early state is not routinely performed. EndoButton position evaluation by XRay was made because this technique was cheap and reliable in Indonesia. There is no consensus on the ideal positioning of EndoButton in compare with functional outcome after ACLR. The study aimed to evaluate anatomic positions of tunnel and fixation devices, and also provide a baseline examination for future controls regarding tunnel placement and fixation devices, and also evaluation functional outcome after ACL procedure and also evaluation of functional outcome after ACLR with IKDC score. Between February 2019 to July 2019, 20 patients aged 17 to 59 years, with post ACL reconstruction were involved in this study. We are evaluating sex, age, affected the side of the knee, complication after an operation, related activity with injury, and evaluation postoperatively with femoral angle measurement Xray AP and lateral view. We also evaluated and correlate post ACRL and functional outcomes with the International Knee Documentation Committee (IKDC) score. The mean age of patients was $28,38 \pm 9,3$ years, (87,15% men and 12,5% women). There is no complication after the operation in all patients. Nine patients (56,3%) affected on the left side, and seven patients (43,8%) affected right-sided. All patients are performed single-bundle augmentation techniques for ACL reconstruction. Five (31,3%) patient has history fall and eleven (68,8%) patients caused by sports activity. All patient has Femoral angle measurement from knee AP view x-rays more than 17o, with minimum 39o and maximum 54o, with mean $46,63 \pm 4,2$. From lateral x rays, we interpreted nine patients (45%) interpreted as shallow and high, and 55% others interpreted as deep and low (optimal). The mean of IKDC score pre-op was $58,1 \pm 4,6$ and means IKDC postoperatively 6 months was $84,68 \pm 5,1$. There was a significant difference in functional outcome between optimal endobutton and not optimal endobutton position group with p -value $< 0,05$. Early post-operative imaging (knee x-rays) provides useful information regarding tunnel placement and fixation devices. It also serves as a baseline examination for future reference. In this study, a single bundle ACL reconstruction shows a satisfying outcome.*

Keywords: *Anterior cruciate ligament; knee; postoperative reconstruction; radiograph.*

INTRODUCTION

The anterior cruciate ligament (ACL) is the most frequently reported injured knee ligament that requires surgical reconstruction.¹ The annual incidence rates of an ACL injury are between 30 and 40 ruptures per 100,000 inhabitants depending on the population.² The ACL reconstruction makes two bone tunnels femur and tibia connected. The graft is fixed to the femur using the EndoButton.^{2,3} Malpositioning of the EndoButton is considered as one of the most common technical errors in ACL reconstruction.⁴ It is estimated that up to 80% of technical failures are based on improper tunnel placement. No study has been reported to evaluate EndoButton position and their correlation with the functional outcome with plain Xray. Xray was chosen because of its reach in the Indonesian population and cheap than Ct scan and MRI.⁵

When used, radiographic measurements show reliable correlation with anatomic dissection measurements of ACL insertion sites and correlation with their functional outcome.^{6,7} Correct endobutton positioning is essential for an optimum clinical outcome in all ACL patients.⁷ The purpose of this paper is to enable the reader to accurately read postoperative radiographs after single-bundle ACL reconstruction, and also evaluation of functional outcome after ACL reconstruction with IKDC score.

RESEARCH METHODS

Between February 2019 to July 2019, 20 patients aged 17 to 59 years, with post ACL reconstruction was involved in this study. We are evaluating sex, age, affected side of knee, complication after operation, related activity with injury, and evaluation postoperatively with x-rays AP (femoral angle measurement) and lateral radiograph, evaluate functional outcome with IKDC (International Knee Documentation) score, we also evaluate the correlation between

functional outcome and position of endobutton after ACL reconstruction.

RESULTS AND DISCUSSION

The mean age of patients was $28,38 \pm 9,3$ years, (87,15% men and 12,5% women). There is no complication after the operation in all patients. Eleven patients (56,3%) affected on the left side, and nine patients (43,8%) affected on the right side. All patients are performed single-bundle augmentation techniques for ACL reconstruction. Six (31,3%) patients have history fall and fourteen (68,8%) patients caused by sports activity. All patient has femoral angle measurement from knee AP view x-rays with minimum 39o and maximum 54o, with mean $46,63 \pm 4,2$. From lateral x-rays, we interpreted nine patients (45%) interpreted as shallow and high, and 55% others interpreted as deep and low (optimal). The mean of IKDC pre-op was 58,1 4,6 and means op IKDC postoperatively 6 months was $84,68 \pm 5,1$. The group of optimal endobutton position was 11 patients and not an optimal patient was 9 patients, with means in each group was $86,9 \pm 1,4$ dan $82,3 \pm 1,6$; with p-value was 0,45($p < 0.05$). There was a significant difference between 2 groups (optimal endobutton position and not optimal endobutton position with correlation with functional outcome.

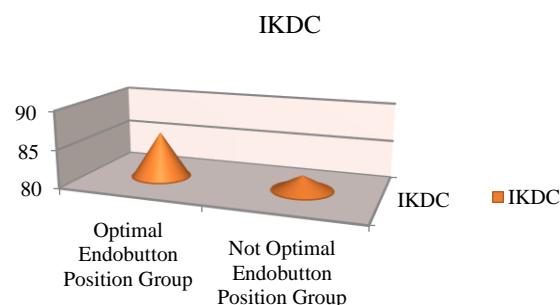


Figure 1. Correlation between endobutton positioning and IKDC (functional outcome).²

Table 1. Main data of Demography, IKDC, and Evaluation x rays

Patient	Age (y.o)	Sex	Affected side	Degree of Endobutton position		Interpretation		IKDC SCORE Pre-op	IKDC SCORE Post-op 6 months
				Femoral Angle	Degree of AP and PD Axis	AP X-ray	Lateral X-ray		
1	36	Male	Left	45°	32°	stable	Shallow and High	54.6	83.2
2	17	Male	Right	44°	15°	stable	Shallow and High	58.4	80.5
3	22	Male	Left	40°	40°	stable	Deep and Low (optimal)	62.7	93.1
4	30	Male	Right	52°	32°	stable	Deep and Low (optimal)	65.8	78.4
5	35	Male	Right	50°	33°	stable	Shallow and High	52.1	80.8
6	59	Male	Left	44°	22°	stable	Deep and Low (optimal)	58.8	87.2
7	27	Male	Right	54°	25°	stable	Shallow and High	51.2	79.4
8	20	Male	Left	52°	20°	stable	Shallow and High	62.9	83.3
9	25	Male	Right	48°	28°	stable	Deep and Low (optimal)	61.3	85.6
10	22	Male	Left	50°	18°	stable	Shallow and High	52.5	94.5
11	22	Female	Left	48°	24°	stable	Shallow and High	55.7	81.4
12	32	Male	Left	39°	22°	stable	Shallow and High	52.3	78.6
13	22	Male	Left	45°	25°	stable	Deep and Low (optimal)	62.5	89.7
14	28	Male	Left	47°	24°	stable	Deep and Low (optimal)	57.4	83.1
15	25	Female	Right	43°	18°	stable	Deep and Low (optimal)	62.6	90.4
16	32	Male	Right	45°	26°	stable	Deep and Low (optimal)	58.9	85.7
17	17	Male	Left	48°	24°	stable	Shallow and High	51.2	79.4
18	42	Male	Left	50°	22°	stable	Deep and Low (optimal)	62.9	83.3
19	34	Male	Right	48°	25°	stable	Deep and Low (optimal)	61.3	85.6
20	29	Female	Left	50°	24°	stable	Deep and Low (optimal)	52.5	94.5

Improper femoral tunnel position has been identified as one of the most frequent errors in failed ACLR. The femoral tunnel should be lateral to the midline of the knee, in the range of 50% to 65% from the lateral edge. In this study, we found 55% data interpreted in optimal (deep and low). Parker et al recommended term and direction describing femoral tunnel placement using a grid, divided in to deep and low and shallow and high.²⁻⁴ This technique was simple to evaluate the femoral tunnel placement (endobutton position). Khalfayan et al emphasis that the femoral tunnel, in lateral view should be more than 60% along Blumensat's line from anterior to posterior. Evaluation with AP view we found mean of the femoral angle and endobutton position angle in 20 patients was $46,63 \pm 4,2$ with minimum 39° and maximum 54° .⁴⁻⁶

We evaluated the functional outcome period 6 months with IKDC score and found that significant differences between endobutton position and functional outcome. There is no previous study evaluated the correlation between functional outcome and endobutton position. In our study, we found a significant correlation between functional outcome and endobutton position ($p < 0,05$).⁷⁻¹⁰

CONCLUSIONS

Simple plain x rays evaluation after ACRL can be a modality as screening and determine the position of endobutton. The optimal position of endobutton correlates with good functional outcome after ACRL in this study.

REFERENCES

1. Kim M, Choi YS, Kim H, Choi NH. Postoperative Evaluation after Anterior Cruciate Ligament Reconstruction: Measurements and Abnormalities on Radiographic and CT Imaging. *Korean J Radiol* 2016;17(6):919-930

2. Parkar AP, Adriaensen ME, Strand T, Inderhaug E, Harlem T, Solheim E. Review Article: How to read post-operative radiographs and CT scans after single-bundle anterior cruciate ligament reconstruction. *Skeletal Radiol*, 2013
3. Bird JH, Carmont MR, Dhillon M, Smith N, Brown C, Thompson P, et al. Validation of a new technique to determine midbundle femoral tunnel position in anterior cruciate ligament reconstruction using 3-dimensional computed tomography analysis. *Arthroscopy*. 2011;27:1259–67.
4. Bernard M, Hertel P, Hornung H, Cierpinski T. Femoral insertion of the ACL. Radiographic quadrant method. *Am J Knee Surg*. 1997;10:14–21. Khalfayan EE, Sharkey PF, Alexander AH, Bruckner JD, Bynum EB. The relationship between tunnel placement and clinical results after anterior cruciate ligament reconstruction. *Am J Sports Med*. 1996;24:335–41.
5. Dargel J, Gotter M, Mader K, Pennig D, Koebeke J, Schmidt- Wiethoff R. Biomechanics of the anterior cruciate ligament and implications for surgical reconstruction. *Strategies Trauma Limb Reconstr*. 2007;2:1–12.
6. Alentorn-Geli E, Lajara F, Samitier G, Cugat R. The transtibial versus the anteromedial portal technique in the arthroscopic bonepatellar tendon-bone anterior cruciate ligament reconstruction. *Knee Surg Sports Traumatol Arthrosc*. 2010;18:1013–37.
7. Saupe N, White LM, Chiavaras MM, Essue J, Weller I, Kunz M, et al. Anterior cruciate ligament reconstruction grafts: MR imaging features at long-term follow-up—correlation with functional and clinical evaluation. *Radiology*. 2008;249:581–90.

8. Prodromos CC, Han YS, Keller BL, et al. Stability results of hamstring anterior cruciate ligament reconstruction at 2- to 8- year follow-up. *Arthroscopy* 2005;21:138–146
9. Lee JS, Kim TH, Kang SY, Lee SH, Jung YB, Koo S, et al. How isometric are the anatomic femoral tunnel and the anteriortibial tunnel for anterior cruciate ligament reconstruction? *Arthroscopy* 2012;28:1504–12.
10. Sohn DH, Garrett WE Jr. Transitioning to anatomic anterior cruciate ligament graft placement. *J Knee Surg* 2009;22:155–60.

